

Maxillary sinus lift with intraoral autologous bone and B – Tricalcium Phosphate: Histological and histomorphometric clinical study

Luis Antonio Aguirre Zorzano ¹, María José Rodríguez Tojo ², José Manuel Aguirre Urizar ³

(1) Profesor Titular de Periodoncia

(2) Investigador. Sección de Medicina Oral. Patología Oral y Maxilofacial

(3) Catedrático de Medicina Bucal. Facultad de Medicina y Odontología. Universidad del País Vasco-Euskal Herriko Unibertsitatea. Leioa, Bizkaia, España

Correspondence:

Dr. Luis Antonio Aguirre Zorzano.

Departamento de Estomatología.

Facultad de Medicina y Odontología.

Universidad del País Vasco / EHU.

Leioa 48940. Bizkaia. Spain

E-mail: laaz@euskalnet.net

Received: 13-01-2007

Accepted: 21-07-2007

Indexed in:

-Index Medicus / MEDLINE / PubMed
-EMBASE, Excerpta Medica
-SCOPUS
-Indice Médico Español
-IBECs

Aguirre-Zorzano LA, Rodríguez-Tojo MJ, Aguirre-Urizar JM. Maxillary sinus lift with intraoral autologous bone and B – Tricalcium Phosphate: Histological and histomorphometric clinical study. Med Oral Patol Oral Cir Bucal. 2007 Nov 1;12(7):E532-6.

© Medicina Oral S. L. C.I.F. B 96689336 - ISSN 1698-6946

ABSTRACT

Introduction: Rehabilitation with implants in the upper maxilla often implies a challenge due to the shortage and quality of the remaining bone. Different kinds of grafts have been described in an endeavour to solve these problems.

Aim: The purpose of this study was to assess the osteoconduction potential of an autogenous bone and B-Tricalcium Phosphate mixture, in the treatment of atrophic upper maxillae.

Materials and Methods: 22 patients were treated using the “sinus lift” technique. All patients had residual bone equal to or greater than 5 mm, the sinus was lifted, bone grafted and implants installed during the same surgical procedure (autologous bone and B-Tricalcium Phosphate). During the implant exposure after the osseointegration period, samples of regenerated bone were taken using a trephine from 5 patients. Paraffin-embedded sections were analysed the structure and tissues percentages. Data were estimated statistically.

Results: Clinical results showed integration of the 42 fixtures installed. Histological analysis showed good integration of the B-Tricalcium Phosphate in the newly formed bone likewise absence of inflammation. Histomorphometric analysis showed a mean bone proportion of 30.7% (range 22.8% – 50.6%).

Conclusions: Results suggest the osteoconductive material B-Tricalcium Phosphate associated with autologous bone obtained through filtration is an appropriate graft for implant treatment of atrophic maxillae, in combination with the sinus lift procedure.

Key words: Bone graft, Tricalcium Phosphate, dental implants, maxillae sinus, morphometric.

INTRODUCTION

Rehabilitation of the upper maxilla edentulous stretches is one of the most complex challenges in implantology. In addition to the generally poor quality of the bone in these regions, there is the maxillary sinus pneumatization process which occurs after dental extractions.

After Boyne and James (1) initial description, the use of bone grafts was proposed to correct this bone deficit. Different materials have been used for these grafts: extra (2,3)

or intraoral (4, 5) autologous bone, allogeneic grafts (6, 7), alloplastic grafts (8, 9), xenografts (10,11) or a combination of the same (12).

In 1996 there was a consensus conference (13) on the “sinus floor lift” procedure. Probably the most important conclusion reached was that the elected grafting material was autologous bone. Nevertheless, the morbidity involved in its use (requires two surgical areas), leads many patients to refuse this treatment.

It has been suggested that the use of demineralised and lyophilised bone or that of bovine origin leads to ethical problems due to the theoretical risk of cross infection transmission.

For this reason, different osteoconductive synthetic materials have been developed (8, 9, 14). Among them is the pure phase of B-Tricalcium Phosphate (B-TP) used successfully in hand surgery, osteology, maxillofacial and implantology surgery, where it has demonstrated its capacity to form bone on reabsorption by the organism (15, 16).

The purpose of this study was to verify the efficacy of a combination of autologous bone obtained through a filter inserted in the surgical aspirator and B-TP as bone substitute in the "sinus lift" procedure for implant placement, in a clinical histological study context.

MATERIALS AND METHOD

Patients

Twenty-two partially edentulous patients, who had previously given their consent, took part in this study. The group comprised 13 women and 9 men, with a mean age of 47 (range 36-69 years) were intervened according to a protocol involving installation of implants and sinus lift in a 1-stage procedure (36 implants Astra ST[®], Astra Tech AB, Mölndal, Sweden). The osseointegration period prior to loading implants ranged between 6 and 11 months.

SURGICAL PROTOCOL

Prior to surgery a radiographic study (orthopantomographs, telerradiography and periapical X-rays) on the patient likewise some study models from which to create a surgical splint to enable correct positioning of the implants.

Immediately prior to the intervention, patients rinsed with a 0.2% chlorhexidine digluconate (Clorhexidina Lacer[®], Lacer S.A., Barcelona, Spain) and disinfected facial skin with povidone iodine (Betadine[®], Asta Medica, Madrid, Spain).

A local anaesthetic with vasoconstrictor (articain 4% with epinephrine 1:50000, Ultracain[®], Normon S.A. Madrid, Spain) was administered to the buccal and lingual side of the areas to be treated. A mediocrestal incision was made on the edentulous side supplemented by buccal releasing incision on the distal surface of the last tooth and in the tuberosity area, raising a full-thickness flap. Afterwards, the osteotomies were prepared for the implants which presented no osseous problems and the bone from drilling was collected using a filter (BoneTrap[®] Astra Tech AB, Mölndal, Sweden) inserted in the surgical aspirator. Using a thick grain diamond bur of 5 mm diameter, we prepared the bone window of variable diameter, at approximately 2mm from the sinus floor, depending on the number of implants to be installed. Once the Schneider membrane had been exposed, we meticulously separated it from the lower edge of the preparation using blunt curettes of different shapes and sizes, endeavouring to maintain its integrity. In one case there was a small tear which was repaired using a collagen membrane (Bio-Gide[®], Geistlich Pharma AG, Wolhusen Switzerland). Afterwards, the material B-TP (Cerasorb[®]

Curasan Phama GmbH, Kleinostheim, Germany), previously soaked in a sterile saline solution, was packed into the medial aspect of the sinus to keep the membrane lifted while the fixtures were installed according to the manufacturer's protocol (Figure 1A). Subsequently the B-TP was mixed with the bone contents collected in the filter, in a proportion ranging between 2:1 and 5:1 depending on the amount of bone collected, which was then packed into the sinus taking care to avoid empty spaces. Next, the mucoperiosteic flap was positioned and closed using horizontal mattress sutures and single stitches. The implants remained submerged between 6 and 11 months, and then subsequently loaded.

All the patients received oral antibiotic treatment with 500mg. of amoxicillin + clavulanic acid (Augmentine[®]) every 8 hours during 7 days, commenced one hour prior to the intervention. To control inflammation after the intervention, the patients were administered one intramuscular 6 mg. dose of Betametasona (Celestone cronodose[®], Shering-Plough S.A., Madrid, Spain) and 40 mg. of Piroxicam (Feldene Flas[®], Pfizer, S.A., Madrid Spain) orally daily while the inflammation persisted. Likewise, the patients rinsed their mouths out with 0.2% chlorhexidine digluconate twice a day during 6 weeks. The suture was removed on the tenth day and the patient controlled monthly.

SECOND SURGERY AND SAMPLE TAKING

After a healing period and under local anaesthetic, a full-thickness flap was raised, and the correct integration of the implants checked, subsequently healing caps were installed (Figure 1B). Afterwards periapical X-rays and a control orthopantomograph were taken.

Bone sample were taken from 5 randomly selected patients using a 2 mm diameter trephine on the lateral sinus wall or an area between the implants. The samples were submerged in 10% buffered formaldehyde and fixed during 12 hours. They were subsequently treated during 12 hours with 10% formic acid and dehydrated in increasing alcohol concentrations and xylol. After 12 hours in paraffin, a mould was created from each sample and cuts of 5 microns made which were stained with haematoxylin and eosin, PAS and Tricromic of Masson-Goldner.

A histomorphometric studied was carried out using an Olympus DP-Soft[®] system with an Olympus BX41 microscope, measuring: a) total biopsy area, b) osseous tissue area, c) material area (Cerasorb[®]), e) dense connective tissue area and d) the rest.

Data were estimated statistically.

RESULTS

Clinical observations

During the sinus lift procedure only one Schneider membrane suffered a small tear which was repaired using a collagen membrane. In all cases the post-operation period was free of complications except for the inflammation and swelling inherent in the surgical procedure.

All the implants presented correct osseointegration and received fixed prostheses. The mean functioning period

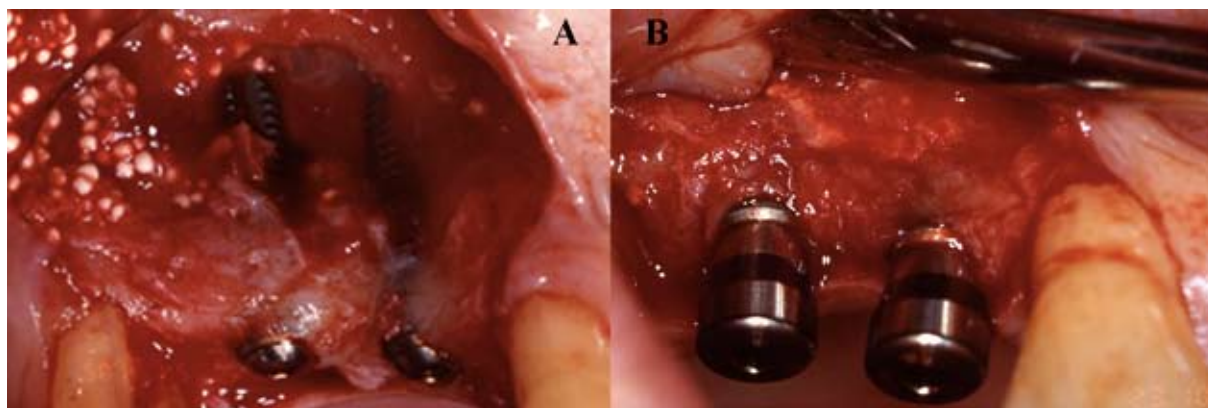


Fig. 1.
 A: Lateral aspect of buccal window after dissection and elevation of sinus membrane and instalation of B-TiP, into the medial aspect of the sinus and implants.
 B: Final result after osteointegration period. We can see the implants with the healing abutments.

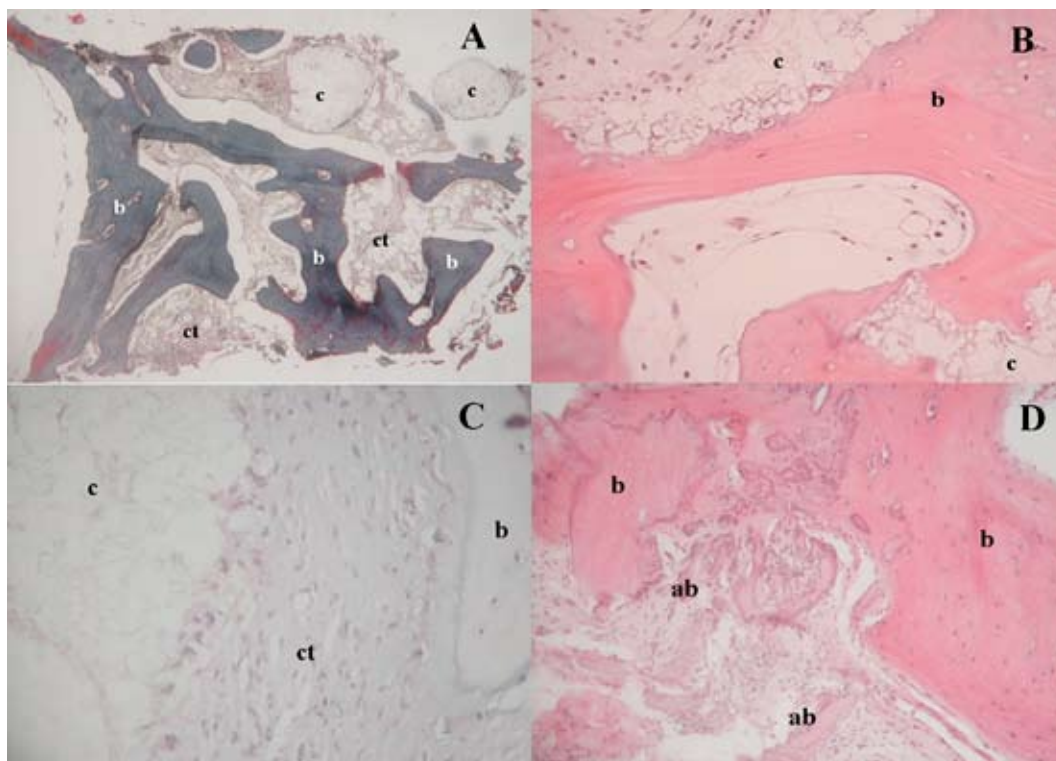


Fig. 2.
 A: Specimen with satisfactory bone density and Cerasorb granules remnants (patient 2) (Masson trichrome, original magnification x4) b=bone, c=cerasorb, ct=connective tissue.
 B: Lamellar bone formation intermingled with Cerasorb remnants (patient 1) (hematoxylin&eosin, original magnification x40) b=bone, c=cerasorb.
 C: Cellular proliferation in relation with Cerasorb remnants, along with peripheral bone apposition (hematoxylin&eosin, original magnification x40) b=bone, c=cerasorb, ct=connective tissue).
 D: Bone formation intermingled with autogenous bone remnants (hematoxylin&eosin, original magnification x25) b=bone, ab=autogenous bone.

of the prostheses is 35 months ranging between 27 and 53 months. After this time, all the implants successfully fulfilled the Alberktsson et al. criteria (18). Radiographically the apical elevation of the sinus floor was observed together with the presence of radiopaque material with greater density than the bone. A year after the graft-

ing this material could still be seen in the periapical X-rays, although with less radiological density. Likewise, the X-rays show partial reabsorption of the grafted volume between the moment of placement and the loading of the implants. This process did not continue in time and the osseous level became stabilised.

Table I. Morphometric data of the samples studied.

	Total Area mm	Bone Area mm	Cearasorb Area mm	Connective Tissue Area mm
Case 1	10.88	5.44 (50.65%)	0 (0%)	0.22 (2%)
Case 2	9.33	2.45 (26.63%)	0.26 (3%)	0.96 (16.24%)
Case 3	11.58	2.65 (22.81%)	0.68 (5.25%)	1.61 (14.22%)
Case 4	27.62	2.69 (24.89%)	3.18 (28.27%)	1.33 (11.65%)
Case 5	6.66	1.88 (28.54%)	1.47 (22.02%)	0.64 (9.41%)
Mean	13.21	3.02 (30.7%)	1.11 (11.7%)	0.95 (10.7%)

HISTOLOGICAL AND HISTOMORPHOMETRIC OBSERVATIONS

The biopsies performed presented a mean size of 13.2 mm, and ripe trabecular bone was observed in all cases.

The osseous trabeculae presented abundant lacunas with osteocytes inside and scarce signs of osseous remodelling (Figure 2).

Remnant granular (Cerasorb®) was recognised in four of the cases studied. These remnants were surrounded by osseous and/or connective tissue (Figure 2).

We observed neither inflammatory phenomena nor foreign body reaction in any of the samples analysed.

The data and percentages of each case and the elements measured appear in the table I.

The osseous area measured was 3.02 mm², (30.7% analysed area) in all cases exceeding 20%. The remnant Cerasorb® area has varied between 0 and 28.2%. The mean connective tissue was 10.7%, and did not exceed 20% in any of the cases.

DISCUSSION

Installation of implants in severely atrophic maxillae is a serious challenge within the field of Implantology. The posterior maxilla zone is a particularly compromised area due to the sinus pneumatization, bone reabsorption after tooth loss or the sum of both circumstances.

In recent years, the procedure known as "sinus lift" has turned out to be a viable predictable treatment for partially or totally edentulous patients with atrophy of the posterior maxilla. This procedure requires the use of bone or biomaterial grafts or a combination of both (14).

Autogenous bone has been shown to be the most efficient material when carrying out this procedure (14). Nevertheless, on many occasions the bone volume required to carry out a sinus lift procedure is such that an extraoral donor zone is required, with subsequent increase in the morbidity involved. For this reason the use of alternative materials, which when combined with autologous bone reduce the

graft volume necessary, has been studied.

The material used in this study (B-TP) has demonstrated its use in the treatment of osseous defects several fields of Medicine (15-17). However, there are few references as to its use in the treatment of dento-maxillofacial defects (19-22).

For our study we mixed B-TP with autologous bone obtained through a filter attached to the surgical aspirator. We consider this procedure capable of providing osteoblasts, pluripotential cells from the marrow and proteins, which might intervene in the bone regeneration process, without the need for a second surgical area to obtain the same.

Szabor et al. (19), in a study of four patients requiring bilateral sinus lifts, they compared the use of autologous bone with B-TP. Their results demonstrated the use of this material to obtain new bone. Histology showed the presence of 29.39% bone in the samples taken from patients on whom this material was used. Individual response had a lot of impact on the results, since those patients who had slow new bone formation, were so in both sinuses regardless of the material used. Our results using B-TP mixed with aspirated bone were similar, with samples showing a mean 30.7% osseous tissue.

Reinhardt and Kreusser (20) treated 50 patients with sinus lifts (39 using 1-step procedure and 11 with 2-step) using B-TP as filling material and installing 101 implants of different kinds. Only 6% of the cases presented post-operation complications (slight sinusitis well controlled with antibiotics), and obtaining integration of 100 implants. The histological study showed reabsorption of the grafted material to be in the same proportion as the neo-osseous formation and absence of inflammatory signs.

Zerbo et al. (21) reported histological results on two cases: sinus lift and large mandibular defect. In both the use of B-FT was demonstrated in the treatment of these defect types, with bone percentages of 20% and 34% in the sample respectively.

Recently, Zsabo et al. (22) have described a multicenter study with a split mouth method of sinus lift procedure, using

B-FT graft in one side and autogenous bone in the other side. After six months of being resting, eighty biopsies were done at the moment to install the implants. Their results did not find any statistical relation to the kind of material graft, the mean bone percentage for B-FT was 36.47% and for the bone 38.34%.

It is difficult to compare our results with those of other studies given the variety of biomaterials used, the different proportions between these and the autologous bone used, disparity at the time of sample taking and even in the sample processing. Likewise, different proportions of regenerated bone with the use of different biomaterials have been described: similar to (19), lower (24,25) or higher (13,22) than ours.

Bearing in mind the limitation of the sample studied and follow-up period of the implants after their loading, what stands out is the 100% success of the implants installed using this procedure. Jensen et al. (14) reported 87.4% success in the deferred procedure and 79.1% with the immediate technique. Tong et al. (26) performed meta-analysis on the successful results published for the different graft materials. With autologous bone implant survival was 90% after 6 to 60 months; whilst with hydroxyapatite combined with autologous bone it was 94% at 18 months and 87% when used alone.

Given the importance of initial stability of implants in their integration, we believe this success may largely be due to the surface and design characteristics of the macro-/microstructure of the implants used in this study, which enabled very good initial stability even with scarce bone volume.

After our study, we can point out the sinus lift procedure is a therapeutical alternative to be considered in patients with osseous atrophy in the posterior zones of the upper maxilla, due to the great predictability of the procedure and little complications encountered. Besides and with the limitations of our study, we can claim that B-TP combined with autologous bone obtained through filtering may be a graft material to be taken into account when performing a sinus lift. Nevertheless, we consider that subsequent studies with a higher number of cases have to be carried out, likewise longer follow-up periods to assess stability in time with these results.

REFERENCES

1. Boyne PJ, James RA. Grafting of the maxillary sinus floor with autogenous marrow and bone. *J Oral Surg.* 1980 Aug;38(8):613-6.
2. Keller EE, Van Roekel NB, Desjardins RP, Tolman DE. Prosthetic-surgical reconstruction of the severely resorbed maxilla with iliac bone grafting and tissue-integrated prostheses. *Int J Oral Maxillofac Implants.* 1987 Summer;2(3):155-65.
3. Tatum H Jr. Maxillary and sinus implant reconstructions. *Dent Clin North Am.* 1986 Apr;30(2):207-29.
4. Gonzalez-Garcia R, Naval-Gias L, Munoz-Guerra MF, Sastre-Perez J, Rodriguez-Campo FJ, Gil-Diez-Usandizaga JL. Preprosthetic and implantological surgery in patients with severe maxillary atrophy. *Med Oral Patol Oral Cir Bucal.* 2005 Aug-Oct;10(4):343-54.
5. Wood RM, Moore DL. Grafting of the maxillary sinus with intraorally harvested autogenous bone prior to implant placement. *Int J Oral Maxillofac Implants.* 1988 Fall;3(3):209-14.
6. Lundgren S, Moy P, Johansson C, Nilsson H. Augmentation of the maxillary sinus floor with particulated mandible: a histologic and histomorpho-

- metric study. *Int J Oral Maxillofac Implants.* 1996 Nov-Dec;11(6):760-6.
7. Hanisch O, Lozada JL, Holmes RE, Calhoun CJ, Kan JY, Spiekermann H. Maxillary sinus augmentation prior to placement of endosseous implants: A histomorphometric analysis. *Int J Oral Maxillofac Implants.* 1999 May-Jun;14(3):329-36.
8. Mazor Z, Peleg M, Gross M. Sinus augmentation for single-tooth replacement in the posterior maxilla: a 3-year follow-up clinical report. *Int J Oral Maxillofac Implants.* 1999 Jan-Feb;14(1):55-60.
9. Wheeler SL. Sinus augmentation for dental implants: the use of alloplastic materials. *J Oral Maxillofac Surg.* 1997 Nov;55(11):1287-93.
10. De Leonardis D, Pecora GE. Augmentation of the maxillary sinus with calcium sulfate: one-year clinical report from a prospective longitudinal study. *Int J Oral Maxillofac Implants.* 1999 Nov-Dec;14(6):869-78.
11. Hallman M, Hedin M, Sennerby L, Lundgren S. A prospective 1-year clinical and radiographic study of implants placed after maxillary sinus floor augmentation with bovine hydroxyapatite and autogenous bone. *J Oral Maxillofac Surg.* 2002 Mar;60(3):277-84; discussion 285-6.
12. Hising P, Bolin A, Branting C. Reconstruction of severely resorbed alveolar ridge crests with dental implants using a bovine bone mineral for augmentation. *Int J Oral Maxillofac Implants.* 2001 Jan-Feb;16(1):90-7.
13. Boeck-Neto RJ, Gabrielli M, Lia R, Marcantonio E, Shibli JA, Marcantonio E Jr. Histomorphometrical analysis of bone formed after maxillary sinus floor augmentation by grafting with a combination of autogenous bone and demineralized freeze-dried bone allograft or hydroxyapatite. *J Periodontol.* 2002 Mar;73(3):266-70.
14. Jensen OT, Shulman LB, Block MS, Iacono VJ. Report of the Sinus Consensus Conference of 1996. *Int J Oral Maxillofac Implants.* 1998;13 Suppl:11-45.
15. Mangano C, Bartolucci EG, Mazzocco C. A new porous hydroxyapatite for promotion of bone regeneration in maxillary sinus augmentation: clinical and histologic study in humans. *Int J Oral Maxillofac Implants.* 2003 Jan-Feb;18(1):23-30.
16. Gruber AAJ. Practical applications of a bone substitute – Beta Tricalcium phosphate - in hand surgery. *Trauma line* 1999; 2: 50-58.
17. Rejda BV, Peelen JG, De Groot K. Tri-calcium phosphate as a bone substitute. *J Bioeng.* 1977 Jan;1(2):93-7.
18. Albrektsson T, Zarb G, Worthington P, Eriksson AR. The long-term efficacy of currently used dental implants: a review and proposed criteria of success. *Int J Oral Maxillofac Implants.* 1986 Summer;1(1):11-25.
19. Szabo G, Suba Z, Hrabak K, Barabas J, Nemeth Z. Autogenous bone versus beta-tricalcium phosphate graft alone for bilateral sinus elevations (2- and 3-dimensional computed tomographic, histologic, and histomorphometric evaluations): preliminary results. *Int J Oral Maxillofac Implants.* 2001 Sep-Oct;16(5):681-92.
20. Reinhardt C, Kreuzer B. Retrospective study of dental implantation with sinus lift and Cerasorb augmentation. *Dent Implantol* 2000; 14: 18-26.
21. Zerbo IR, Bronckers AL, De Lange GL, Van Beek GJ, Burger EH. Histology of human alveolar bone regeneration with a porous tricalcium phosphate. A report of two cases. *Clin Oral Implants Res.* 2001 Aug;12(4):379-84.
22. Szabo G, Huys L, Coulthard P, Maiorana C, Garagiola U, Barabas J, et al. A prospective multicenter randomized clinical trial of autogenous bone versus beta-tricalcium phosphate graft alone for bilateral sinus elevation: histologic and histomorphometric evaluation. *Int J Oral Maxillofac Implants.* 2005 May-Jun;20(3):371-81.
23. Hoegel F, Mueller CA, Peter R, Pfister U, Suedkamp NP. Bone debris: dead matter or vital osteoblasts. *J Trauma.* 2004 Feb;56(2):363-7.
24. Yildirim M, Spiekermann H, Biesterfeld S, Edelhoff D. Maxillary sinus augmentation using xenogenic bone substitute material Bio-Oss in combination with venous blood. A histologic and histomorphometric study in humans. *Clin Oral Implants Res.* 2000 Jun;11(3):217-29.
25. Wheeler SL, Holmes RE, Calhoun CJ. Six-year clinical and histologic study of sinus-lift grafts. *Int J Oral Maxillofac Implants.* 1996 Jan-Feb;11(1):26-34.
26. Tong DC, Rioux K, Drangsholt M, Beirne OR. A review of survival rates for implants placed in grafted maxillary sinuses using meta-analysis. *Int J Oral Maxillofac Implants.* 1998 Mar-Apr;13(2):175-82.