

Use of bone plates and screws to manage chronic mandibular dislocation

Marcelo Rodrigues Azenha¹

¹ Oral and Maxillofacial Surgeon, São Paulo, Brazil.

Correspondence:

Dr. Marcelo Rodrigues Azenha

Rua Sebastião Lins 2-44, Bauru, SP, Brazil

Email: marceloazenha@usp.br

Received: 06/04/2010

Accepted: 02/05/2010

Rodrigues Azenha M. Use of bone plates and screws to manage chronic mandibular dislocation. J Clin Exp Dent. 2010;2(3):e133-7.
<http://www.medicinaoral.com/odo/volumenes/v2i3/jcedv2i3p133.pdf>

<p>Article Number: 50301 http://www.medicinaoral.com/odo/indice.htm © Medicina Oral S. L. C.I.F. B 96689336 - eISSN: 1989-5488 eMail: jced@jced.com</p>
--

Abstract

Different treatment modalities are described in literature to treat mandibular recurrent dislocation, including intra-capsular esclerosant injections, articular eminence reduction, soft tissues suture to limit condilar movement, and grafts or implants to create mechanical interference, like zygomatic arch down fracture or articular eminence increase by bone plates. In this paper, a patient with mandibular recurrent dislocation episodes were eliminated after bilateral fixation of bone plates to the lateral sur-face of the zygomatic arch to restrict mandibular movements. One arm of the plate was extended me-dially just below the articular eminence and fixed at lateral zygomatic arch portion by two screws. The surgical technique is described and 24 months follow-up period is demonstrate with excellent recovery and functional activities. The temporomandibular joint (TMJ) function was unimpeded and no recu-rrence of condilar dislocation was observed. We concluded that this technique is safe and efficient to hinder dislocations of mandible, preserve the TMJ initial characteristics, and prevent abnormal condi-lar movements over the eminence.

Key words: *Temporomandibular joint, surgery, recurrent mandibular dislocation.*

Introduction

Chronic mandibular recurrent dislocation (CMRD) is defined as the complete loss of articular relationships, during mouth-wide opening, between the articular fossa of the temporal bone and the condyle-disk complex. It has been the most frequent pathogenetic factors involved in this pathology: previous facial trauma, abnormal chewing movements, temporomandibular joint (TMJ) ligaments, capsule laxity, and masticatory muscles disorders. During masticatory movements, rapidly and smooth teeth contacts do not overload the TMJ, differing from para-functional activities that are responsible of the most problems seen at teeth structures, periodontium, and TMJ region (1). When conservative treatment modalities do not show any improvement, including muscular relaxing plates, teeth splints and muscular physiotherapy, the surgical procedures are indicated (2). This situation (CMRD) is frequently associated to non cooperative patients like mentally retarded patients, epileptic people, and syndromes.

Different treatment modalities are described in literature to treat CMRD, including intracapsular esclo-resant injections, articular eminence reduction or eminectomy, soft tissues suture to limit condilar movement, and grafts/implants to create mechanical interference, like zygomatic arch down fracture or articular eminence in-

creasing with bone plates and screws (3-6).

Buckley and Terry (4) described a method to treat CMRD using a bone plate fixed to zygomatic arch to limit anteriorly condyle translation, been this technique refuted by Kent (7) arguing the plate might lead to trauma of the condyle reporting a case where a mesh fixed to the zygomatic arch fractured due to condyle pressure. A similar method was successfully described using miniplates to increase the height of the articular eminence (6).

The technique showed in this paper aims to elevate the articular tubercle in a patient presenting CMRD without resolution after conservative treatment. This surgery restricts excursions of the mandibular condyle and prevents it from slipping and lodging anteriorly to the articular tubercle and is considered a simple, predictable and reversible technique.

Report of a Case

A 43-year-old patient presented to Oral and Maxillofacial Surgery Department complaining of bilateral pre-auricular acute pain, history of multiple CMRD in the last 2 years, and episodes of bruxism. Radiographic exam confirm dislocation of both mandibular joint, shallow fossa and low angle of the anterior slope of the fossa (8). Patient's medical history was uneventful. Temporary success was obtained after manual condyle reposition-

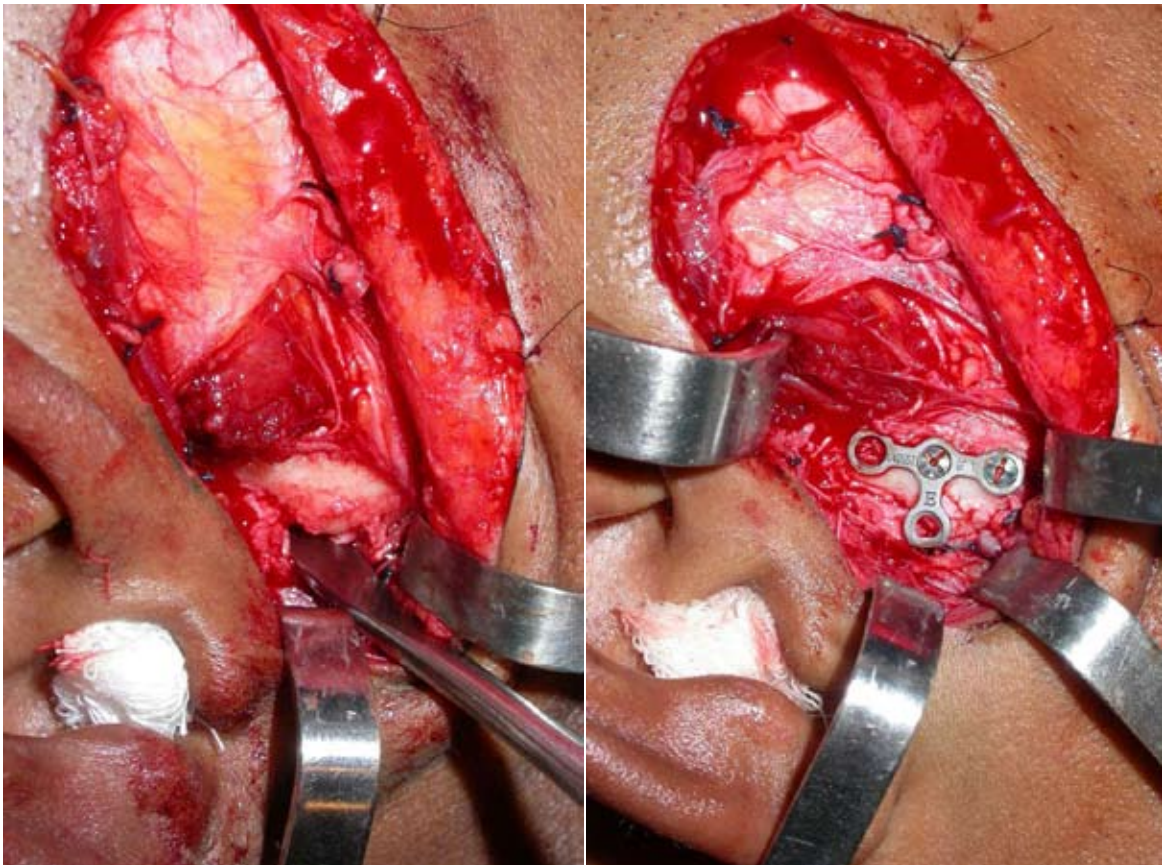


Fig.1. Subperiosteal divulsion anteriorly to articular capsule creating a space to fix the bone plate (A). Bone plate fixed at lateral portion of zygomatic arch with 2 monocortical screws (B).

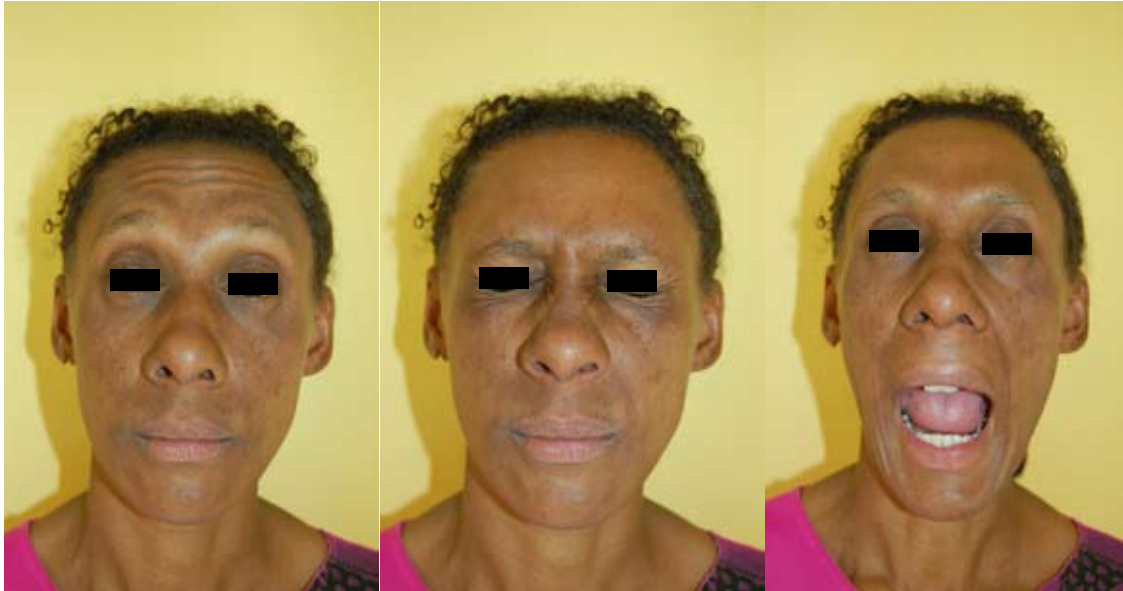

Fig.2. No facial nerve damage following the surgical procedure.

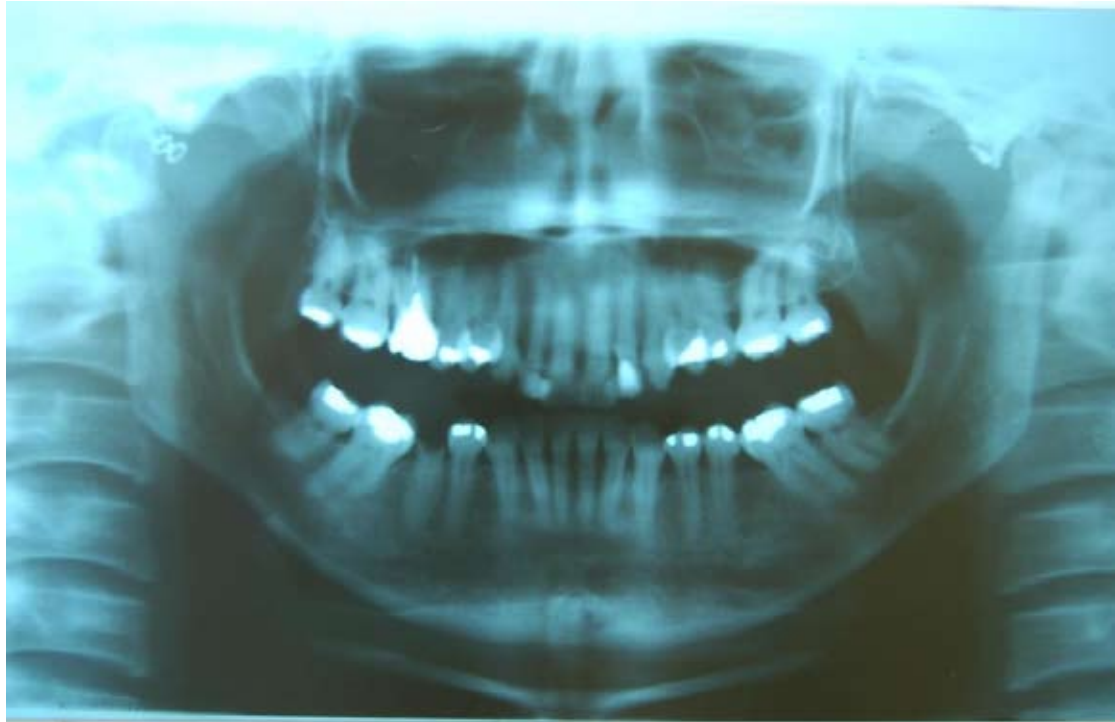

Fig.3. 24 months post-operative panoramic radiography with stable materials at articular eminence.

ning but this maneuver had to be performed under local anesthesia due to patient's anxiety and the difficult to reduce the dislocation. Occlusal splints, restriction of mandibular movements, physiotherapy, and medication were attempted without improvement during 8 months. After failure to solve patients' problem with conservative treatment the surgical procedure to fix bone plates at both articular eminency was proposed to the patient to restrict condyle movements and eliminate CMRD. Under general anesthesia at hospital facilities a pre-auricular incision with an extension to the tempo-ral region

with a number 15 blade was made followed by blunt dissection until temporal muscular fascia and a 45° incision to reach the articular eminence. The lateral aspect of the articular eminence and zygomatic arch were exposed, with no damage to glenoids fossa region. Condyle passive move-ments, as laterality, protrusion and maximal mouth opening were done to determine the contacts between the condyle pole and the articular eminence. With the condyle located over the most inferior portion of the articular eminence, a subperiosteal dissection was performed directly to articular capsule creating a space

to fix the plate. Previously to bone plate insertion, it was bended to create the new articular eminence height, been fixed with 2 screws (6 mm) at lateral portion of zygomatic arch (Fig. 1).

Maximal mouth movements were done to check stability and the exactly location of the bone plate. The left side was then operated using the same technique and fixation material. The incisions were closed in layers and neither inter-maxillary fixation nor drainage apparatus were used. The patient was able to realize normal mandibular movements 24 hours after surgery and no facial nerve damage was observed (Fig. 2). Radiographic and clinical exams after 24 months demonstrated an excellent overcome and perfect stability of the implants at both articular eminences (Fig. 3) with no recurrences of mandibular dislocation episodes.

neither inter-maxillary fixation nor drainage apparatus were used. The patient was able to realize normal mandibular movements 24 hours after surgery and no facial nerve damage was observed (Fig. 2). Radiographic and clinical exams after 24 months demonstrated an excellent overcome and perfect stability of the implants at both articular eminences (Fig. 3) with no recurrences of mandibular dislocation episodes.

Discussion

Bone plates at articular eminence have been used as mechanical barrier to limited mandibular movements with great vantages to articular eminence reduction, aiming to stop CMRD (4-6), been a less invasive procedure, reversible and with no restriction of mandibular movements at post-operative period. Recurrence rate of this procedure is low and facial pain is considerably reduced after bone plate fixation at articular eminency (9). A retrospective study was presented with 11 patients that were submitted to bone plate installation at articular eminence to prevent CMRD, with only one case of recurrence, demonstrating a high success of this treatment modality (3). Similar findings are demonstrated after evaluation of 13 patients treated with this technique after a follow up of at least 30 months (10). Shibata et al. (11) evaluated 9 patients and found only 1 case of miniplate fracture but no recurrence of dislocation. Bakardjiev et al. (12) performed fixation of bone plates at zygomatic arch to restrict condylar movement after recurrent episodes of mandibular dislocation in two patients. Six months postoperatively, TMJ function was unimpeded and there was no recurrence of condylar dislocation. This works are in agreement with our findings with no recurrence after 24 months of follow up, and totally pain relieve.

Kuttenberger and Hardt (9) affirms that bone plates fixed at articular eminency are not safe procedures due to its weakness. They report an incidence of 35% of failure after a follow-up of 20 patients for at least 2 years and due to that they do not recommend miniplate eminoplasty as

the treatment of choice for mandibular dislocation. After clinical experience performing many surgeries to treat CMRD with bone plate fixation at articular eminency we believe this technique has specific indications, like non-compliant patients, shallow articular eminency, and excessive ligament laxity. These findings are in disacordance to Cardoso et al. (13). After compare miniplate eminoplasty to eminectomy the authors didn't find difference between these techniques and neither of them demonstrated recurrence. The goals of these treatments are either to restrict mandibular translation or to remove eminence obstacle (eminectomy), thus preventing mandibular dislocation or locking anterior to the articular eminence. Even knowing miniplate eminoplasty and eminectomy present similar results the last one is the most widely accepted technique to treat CMRD but was not used in our case due to patient anatomical eminency characteristics.

The patient demonstrated a reduction of mouth opening of 4 milimeters at immediate post-operative period, with similar results been demonstrated by other authors (14), affirming that after one year the mouth opening returned to normal and was stable. The only disadvantage of this technique compared to eminectomy is the reduction of maximal mouth opening, without functional limitation. At pre-operative period the patient opened its mouth 41 mm right before mandibular dislocation. Immediate post-operative period demonstrated a mouth opening of 37 mm and during last follow-up mouth opening was of 40 mm demonstrating a satisfactory jaw functions.

It is recommended that the bone plate installation must be done at both articular region, to diminish the chances of CMRD at one side and the development of assymmetric conditions (8). Even after done this procedure only in one TMJ, Iizuka et al. (5) did not observe complications like mandibular deviation during mouth opening or articular pain. At this work, the patient was submitted to surgical procedure at both articulations due to bilateral CMRD and no mandibular deviation during mouth opening was observed.

The various methods of mechanical restriction of the movements of the lower jaw include the down-fracturing of the zygomatic arch, implantation of Vitallium mesh, bone plate/screws and soft tissues suture as was mentioned above. By using an osteosynthesis plate to 'elevate' the tuberculum, movement of the condyle was restricted. A long follow-up period did not show any abnormality to TMJ function and no recurrences of the chronic dislocation was observed (4,6,11). Eminoplasty can perhaps be performed using arthroscopic surgery as a less invasive therapeutic alternative (15).

It was observed that the bone plate surgical procedure to eliminate CMRD is a safe treatment, with good results, simple to be done, and reversible. No alterations to normal function of TMJ were observed. The plate should

be fixed at least with 2 screws to avoid looseness of the material.

References

1. Williamson EH, Lundquist DO. Anterior guidance: its effect on electromyographic activity of the temporal and masseter muscles. *J Prosthet Dent.* 1983;49:816-20.
2. Dimitroulis G. The role of surgery in the management of disorders of the temporomandibular joint: a critical review of the literature. Part 2. *Int J Oral Maxillofac Surg.* 2005;34:231-7.
3. Lawlor MG. Recurrent dislocation of the mandible: treatment of ten cases by the Dautrey procedure. *Br J Oral Surg.* 1982;20:14-21.
4. Buckley MJ, Terry BC. Use of bone plates to manage chronic mandibular dislocation: report of cases. *J Oral Maxillofac Surg.* 1988;46:998-1003.
5. Iizuka T, Hidaka Y, Murakami K, Nishida M. Chronic recurrent anterior luxation of the mandible. A review of 12 patients treated by the LeClerc procedure. *Int J Oral Maxillofac Surg.* 1988;17:170-2.
6. Puelacher WC, Waldhart E. Miniplate eminoplasty: a new surgical treatment for TMJ-dislocation. *J Craniomaxillofac Surg.* 1993;21:176-8
7. Kent JN. Use of bone plates to manage chronic mandibular dislocation: report of cases. *J Oral Maxillofac Surg.* 1988;46:998-1003.
8. Williamson RA, McNamara D, McAuliffe W. True eminectomy for internal derangement of the temporomandibular joint. *Brit J Oral Maxillofac Surg.* 2000;38:554-60.
9. Kuttnerberger JJ, Hardt N. Long-term results following miniplate eminoplasty for the treatment of recurrent dislocation and habitual luxation of the temporomandibular joint. *Int J Oral Maxillofac Surg.* 2003;32:474-9.
10. Chausse JM, Richter M, Bettex A. Deliberate, fixed extra-articular obstruction. Treatment of choice for subluxation and true recurrent dislocation of the temporomandibular joint. *J Craniomaxillofac Surg.* 1987;15:137-40.
11. Shibata T, Yamashita T, Nakajima N, Ueda M, Ishijima T, Shigezumi M, et al. Treatment of habitual temporomandibular joint dislocation with miniplate eminoplasty: a report of nine cases. *J Oral Rehabil.* 2002;29:890-4.
12. Bakardjiev A. Treatment of chronic mandibular dislocations by bone plates: two case reports. *J Craniomaxillofac Surg.* 2004;32:90-2.
13. Cardoso AB, Vasconcelos BC, Oliveira DM. Comparative study of eminectomy and use of bone miniplate in the articular eminence for the treatment of recurrent temporomandibular joint dislocation. *Braz J Otorhinolaryngol.* 2005;71(1):32-7.
15. Sailer HF, Antonini N. Results of the LeClerc operation in habitual temporomandibular joint and discuss articularis luxation. *Fortschr Kiefer Gesichtschir.* 1980;25:43-5.
15. Sato J, Segami N, Nishimura M, Suzuki T, Kaneyama K, Fujimura K. Clinical evaluation of arthroscopic eminoplasty for habitual dislocation of the temporomandibular joint: comparative study with conventional open eminectomy. *Oral Surg Oral Med Oral Pathol Oral Radiol Endod.* 2003;95:390-5.