

Dental considerations for the patient with renal disease

Silvia Martí Álamo ¹, Carmen Gavaldá Esteve ¹, M^a Gracia Sarrión Pérez ¹

¹ Dentist

Correspondence:
San Vicente mártir st., 102, 20
46007 Valencia
E-mail: silviamartialamo@hotmail.es

Received: 05/05/2010
Accepted: 06/12/2010

Martí Álamo S, Gavaldá Esteve C, Sarrión Pérez MG. Dental considerations for the patient with renal disease. J Clin Exp Dent. 2011;3(2):e112-9
<http://www.medicinaoral.com/odo/volumenes/v3i2/jcedv3i2p112.pdf>

Article Number: 50304 <http://www.medicinaoral.com/odo/indice.htm>
© Medicina Oral S. L. C.I.F. B 96689336 - eISSN: 1989-5488
eMail: jced@jced.es

Abstract

Chronic renal disease (CRD) is the renal disease that manifests oral consequences most frequently, and it is defined as a progressive and irreversible decline in renal function associated with a reduced glomerular filtration rate (GFR). The most frequent causes of CRD are diabetes mellitus, arterial hypertension and glomerulonephritis. CRD is classified in 5 stages – from kidney damage with normal or increased GFR to renal failure.

In order to quantify the CRD, renal function is measured using the GFR, which is estimated using creatinine clearance (CC). This CC is used for dose adjustment of drugs. In dental practice, the function of the kidneys can be measured indirectly through plasmatic creatinine (Cr), that can be related to the CC using several formulas. The treatment of CRD includes dietary changes, correction of systemic complications, and dialysis or the receipt of a renal graft in severe cases.

The importance of CRD for the dental practitioner lies in the fact that an increasing number of patients with this disease will probably demand dental treatment, and that up to 90% of them will show oral signs and symptoms related to this systemic disease. Dental management must be adapted to these patients' special conditions, as a greater bleeding tendency, hypertension, anemia, drug intolerance, increased susceptibility to infections and the presence of several oral manifestations associated with either the disease or its treatment.

Key words: *Chronic renal disease, dental considerations, dental management, oral manifestations.*

Introduction

Chronic renal disease (CRD), a progressive and irreversible decline in renal function, is the renal disease with the most implications in dentistry, so this paper is focused on this pathology. Kidneys have the following functions: filtering waste metabolic products, preservation of the electrolytic composition and the volume of the extracellular liquid, regulation of the acid-base balance and endocrine function (synthesis of prostaglandins, erythropoietin, rennin, vitamin D,- involved in bone metabolism- and others) (1).

As this process develops and the number of functional units of the kidney or nephrons diminishes, the glomerular filtration rate (GFR) falls, while serum levels of urea rise, until approaching the stage of renal failure if the patient is not treated. The signs and symptoms in patients with renal failure are known as “uremic syndrome” (1-3).

Normal GFR values are approximately 120- 130ml/ minute/ 1.73 m², and vary according to age, gender and body size (4, 5).

This fall is usually measured by creatinine clearance (CC), which gives an acceptable approximation of the value of GFR (6). In dental practice, the function of the kidneys can be assessed indirectly through plasmatic creatinine (Cr). Normal values of serum Cr are 0.5-1.4 mg/dl; in patients with renal insufficiency, Cr will be of 1.5 mg/dl or more. Plasmatic Cr can be related to CC using several formulas, such as Cockcroft-Gault or MDRD (modified diet in renal disease formula).

Presently, the classification of chronic renal disease is guided by the National Kidney Foundation’s K-DOQI guides (The National Kidney Foundation Kidney Disease Outcomes Quality Initiative) of 2002, which include the following situations:

- Kidney damage during at least 3 months with or without a decrease in glomerular filtration rate
- Filtration rate < 60 ml/min/1.73 m² during more than 2 months with or without kidney damage (4, 7).

In Spain, the exact prevalence of renal pathology remains unknown. According to the EPIRCE study (Epidemiology of Chronic Renal Insufficiency in Spain), the prevalence of CRD ranges between 1/3 of the population and a 0.7%, depending on the study considered (7).

Diabetes mellitus, arterial hypertension and glomerulonephritis are the most important etiologic factors of CRD (3). Treatment of the chronic renal insufficiency includes dietary changes, correction of systemic complications, and dialysis or a renal graft (3).

The most common cause of death in patients with end stage renal failure is cardiac arrest, followed by infection and malignancy (2).

These patients can suffer a spectrum of oral manifestations and dental treatment must be adapted to the systemic disease. Therefore, the objectives of this paper are,

firstly, to do a review of literature about chronic renal disease and its repercussions of this disease in dentistry; and, secondly, to summarize the management strategies that can be put into practice in the dental office to treat these patients.

Material and Methods

In order to do an update on oral manifestations and dental considerations for these patients, we searched for articles from the PubMed- Medline database using the following key words: “chronic kidney disease”, “renal failure”, “renal disease”, combined with: “antibiotic use”, “cyclosporine”, “dental”, “dental management”, “detection”, “epidemiology”, “neurological manifestations”, “oral health”, “oral manifestations”, “periodontal disease”, “tacrolimus”, “uremic stomatitis”, “xerostomia”; “dialysis”, combined with “oral manifestations” y “renal osteodystrophy”; and, finally, “kidney transplant” with “malignant tumors”, “Kaposi sarcoma” and “supplemental corticosteroids”. The search was limited to articles in English or Spanish and published during the last 15 years. Twenty- two articles were used (12 reviews of literature – 5 of them being systematic reviews), 4 transversal studies, 2 series of clinical cases, 1 randomized clinical assay, 1 letter to the editor and 1 panel of experts).

Results

Oral manifestations. Up to 90% of patients with renal insufficiency show oral signs and symptoms in soft and hard tissues, some of them being a cause of the disease itself and others deriving from the treatment of the pathology (1).

The diminished function of the kidneys results in an increase in the levels of urea in the blood and also in the saliva, where it will turn into ammonia. For this reason, uremic individuals have a characteristic halitosis (*uremic fetor*), which also occurs in about one-third of hemodialyzed patients. This halitosis is related to another manifestation: the perception of an unpleasant, metallic taste. Apart from urea, other factors possibly implied are the increase in the concentration of phosphates and proteins and changes in the pH of saliva (1, 3, 8). Also, these patients can refer sensitive disturbances, like altered taste sensations –especially, sweet and acid flavors-. These can be due to the high levels of urea, the presence of dimethyl- and trimethyl- amines, or low zinc levels (due to the malabsorption derived from gastrointestinal disorders). There can also be a burning sensation in the lips and tongue, of a neuropathic origin (9) or even a sensation of an enlarged tongue (3). A decrease in salivary secretion occurs as a consequence of liquid intake restrictions, secondary effects of medication (mainly antihypertensives), possible glandular involvement (atrophy of minor salivary glands’ parenchyma), and

mouth breathing. This manifestation is associated with the loss of taste perception (1, 3, 8). Sometimes these individuals are afflicted by anemia due mainly to the decrease in the synthesis of erythropoietin, which can be clinically observed as a skin and mucosa paleness (5). Uremic stomatitis is an oral complication of unknown etiology and it is relatively uncommon (9), usually seen in patients with an end stage or untreated renal disease (1, 10). Clinically, it is characterized by the presence of erythematous lesions which are localized or generalized. These lesions are covered by a pseudomembranous exudate that can be removed, leaving an intact or ulcerated mucosa (8). As there are no histological pathognomonic signs of this manifestation, the definitive diagnosis will be made combining clinical findings and excluding other diseases with the histopathology (9). It does not require a specific treatment and an involution will usually occur after uremia is restored (1); but in order to assist lesion healing, 10% hydrogen peroxide gargles (1:1 in water), 4 times a day, can be recommended (8).

With regard to dental anomalies in these patients, delayed eruption in children with CRD has been reported. Another sign frequently found in children is the presence of enamel hypoplasias, due to alterations in calcium and phosphorus metabolism (5). In adults with CRD, narrowing or calcification of the pulp chamber can occur. This is reportedly more severe in graft recipients than in individuals receiving hemodialysis (3).

There is no consensus between authors whether dental caries are more prevalent in patients with CRD; however, there is no firm evidence to suggest that there is (3). Sometimes an antibacterial effect has been attributed to the increase of the pH (due to urea hydrolyzation by saliva), which suggests a protective function against caries (5). However, non-cariou tooth tissue loss is more prevalent in individuals with CRD than in the general population. This may be due to nausea, esophageal regurgitation, or induced vomiting in bulimia nerviosa (in patients who dislike the restrictive diet, which is suggested as a part of the treatment) (3). The majority of studies agree that there is a greater incidence of periodontal disease, bone loss, recessions and deep periodontal pockets (2).

Other oral manifestations of the CRD are related to renal osteodystrophy. This is a late sign of renal disease due to alterations in calcium and phosphorus metabolism, abnormal metabolism of vitamin D and the compensatory hyperactivity of parathyroid glands (secondary hyperparathyroidism). It is characterized by the following signs: bone demineralization, decreased trabeculation, decreased thickness of cortical bone, ground-glass appearance of bone, metastatic soft-tissue calcifications, radiolucent fibrocystic lesions, radiolucent giant cell lesions, lytic areas of bone, jaw fracture (spontaneous or after dental procedures), abnormal bone healing after extraction, and, sometimes, dental mobility as a consequence

of loss of substance in the bone (1).

Bleeding tendency in these patients may be due to factors depending on the disease itself, like alterations in platelet aggregation and renal anemia (secondary to deficient erythropoiesis) (2, 6); and to dialysis, which diminishes platelet recount due to mechanical damage and heparin anticoagulation during this process. For that reason, it can be concluded that hemodialysis predisposes to ecchymosis, petechiae and hemorrhage in the oral mucosa (8).

Oral hygiene of patients receiving hemodialysis is usually poor, so deposits of calculus (3) and plaque may be increased (11).

Treatment received by patients with renal disease also produces oral clinical manifestations. In particular, lichenoid disease may arise, associated with antihypertensive medication (diuretics, beta-blockers) (3).

Kidney-transplanted patients are given a lifelong immunosuppressive therapy, and therefore more susceptible to infections and to the development of malignant neoplasms (12). Furthermore, they are frequently afflicted by a secondary effect of the medication: gingival overgrowth. Where fungal infections are concerned, there are mainly lesions related to *Candida albicans*. Angular cheilitis has been reported in more than 4% of patients receiving hemodialysis or who have undergone transplantation. Other forms of candidosis have been reported in allograft recipients: pseudomembranous (1.9%), erythematous (3.8%), chronic atrophic – also called prosthetic stomatitis (3.8%). It should be highlighted that these figures may underestimate the increased susceptibility of immunosuppressed allograft recipients to fungal infection, since systemic anti-fungal agents are commonly prescribed prophylactically (3).

The herpes group of viruses, in particular cytomegalovirus (CMV) and herpes virus simplex (HSV), are frequently associated with immunosuppressed organ transplant recipients. Mucosal ulceration is often associated with CMV, having a predilection for the lateral borders of the tongue (12). Due to this immunosuppression, a reactivation of HSV, characterized by the onset of recurrent, severe and long-standing infections. Clustered vesicles on an erythematous base may arise, or, more atypically, a lone lesion. They can appear either in labial mucosa or intraorally, having a predilection, in the latter, for keratinized epithelium. Vesicles on mucosal surfaces rapidly erode and leave an ulcerated area (12, 13).

In the case of recurrent infections of HSV in these patients, doses of 400 mg of acyclovir can be administered orally, 3 times a day during 10 days or more (usually, more than 2 weeks) (13). Long-standing immunosuppression also predisposes to infection by herpes human virus-8 (HHV-8), related to Kaposi's sarcoma (3). Hairy leukoplakia occurs in immunosuppressed patients (11% of renal transplant recipients), and it is associated with

the Epstein- Barr virus. It is important to make a differential diagnosis in cases of chronic pseudomembranous candidosis –white lesions that can be removed- (12). Regarding malignant tumors, lymphomas, Kaposi's sarcoma (KS) and oral squamous cell carcinoma of the lip, are the most frequent in the stomatologic area. Approximately 86% of the lymphomas are Non- Hodgking lymphomas (NHL) of B cells (12).

Gingival overgrowth (GO) secondary to the immunosuppressive therapy is the most studied oral manifestation. An estimated 30% of dentate patients medicated with cyclosporine alone experience clinically significant gingival overgrowth (GO). When patients are medicated with a combination of cyclosporine and nifedipine, the prevalence of gingival overgrowth increases to 50%. This effect occurs within 3 months of treatment. Age is an important determining factor for this unwanted effect, since children are more susceptible than adults. The pathogenesis of this disorder is multifactorial, but it is thought that the key factors are drug variables, plaque-induced inflammation, the susceptibility of gingival fibroblasts and also genetic factors (12), as not all patients treated with Cs develop gingival overgrowth (14). There are multiple pharmacologic agents that can produce the unwanted effect of GO, such as anticonvulsivants or antiepileptics (phenytoin, sodium valproate, phenobarbital, vigabatrin), immunosuppressants (cyclosporine), calcium channel blockers (nifedipine, verapamil, diltiazem, oxodipine, amlodipone) and others. Although some slight histopathological differences have been found, gingival overgrowth produced by different drugs is clinically indistinguishable. The combination of drugs that most frequently produces this side effect is Cs and nifedipine, used in renal transplant recipients (15). Gingival overgrowth is usually confined to attached gingiva but may extend coronally and interfere with occlusion, mastication and speech. This overgrowth, which normally begins at the interdental papillae, is more common in the anterior segments of the mouth and on labial surfaces of teeth (15). It does not seem to have a predilection for the maxilla or the mandible (16). It has also been noted that overgrowth associated with the canine teeth is significantly greater. GO does not seem to arise in edentulous patients or edentulous spaces (15). Several authors have attempted to find a relationship between this manifestation and the drug dosage and its serum concentration, but the results obtained are not conclusive (3, 15, 16).

The role of plaque in Cs induced GO has been discussed in literature, but it has not been possible to determine if GO is a cause or a consequence. Plaque accumulation associated with the difficulty in maintaining proper oral hygiene, and also other local irritant factors (prosthesis, brackets, etc.), make gingival inflammation worse, and increase the severity of GO (14). Improvement of oral hygiene achieves a reduction in GO related to cyclo-

porine (3).

Cs has many side effects, including GO, which this has motivated the search of therapeutic alternatives. Recently, tacrolimus (FK506, Prograf®), rapamycin (RS 61443) and mophetil mycophenolate (CellCept®) have been used. However, they are more expensive and their side effects are still not well- known. For these reasons, in the majority of cases, Cs remains the first option (17).

Dental considerations and management of the patient with chronic renal disease. The most important features in these patients are bleeding tendency, hypertension, anemia, drug intolerance, increased susceptibility to infections and the presence of several manifestations associated with either the disease or its treatment (1).

Studies have been published concerning increased susceptibility to infective endocarditis and vascular access infections produced by oral origin bacteria in patients undergoing hemodialysis. De Rossi et al (1), in their review published in 1996, indicated antibiotic prophylaxis in hemodialyzed patients who were undergoing an invasive dental procedure. However, a more recent review by Lockhart et al (18) (2007), pointed out the lack of scientific evidence to prescribe antibiotic prophylaxis to these patients, although traditionally most authors have recommended it. Valvulopathies, particularly cardiac valvular calcification secondary to hyperparathyroidism, are frequent in this population. This condition, in itself, suggests antibiotic prophylaxis, as recommended by the AHA (American Heart Association) (6, 18, 19). In the consensus document of Gutierrez et al (19), renal insufficiency is considered a risk condition for infective endocarditis if the patient does not have a good control of the disease.

Many antibiotics are actively removed by the kidney, so and adjustment of the dosage by amount or by frequency is required (20). Penicillin (and its derivatives, such as amoxicillin), clindamycin and cephalosporins are the preferred antibiotics for these patients. In the case of non- narcotic analgesics, paracetamol is the best choice. It is preferable to avoid the remaining non- steroidal anti- inflammatory drugs (ibuprofen, naproxen and sodium diclofenate), as they produce hypertension. Benzodiazepines can be prescribed without dose adjustment. Narcotic analgesics (codeine, morphine, phenthanile) do not need a dose adjustment either (2). Table 1 shows dose adjustment of some of the most used drugs in dentistry, depending on creatinine clearance.

With regard to GO, when it is severe, a surgical treatment should be performed (gingivectomy). The clinical decision of performing the surgery is based generally in the presence of functional discomfort and esthetic alteration. Nevertheless, this treatment is not definitive: estimated recidives account for a 50%. A change in the immunosuppressive therapy is an alternative to surgical treatment, but it is not always possible. There are some good alter-

DRUGS	DOSE ADJUSTMENT ACCORDING TO CREATININ CLEARANCE		
	Normal dose	Dose with CC 10- 50 ml/ min	Dose with CC <10 ml/ min
ANTIBIOTIC			
Amoxicillin	500/ 1000 mg/ 8 h	500/ 1000 mg/ 8-12 h	500/ 1000 mg/ 12- 24 h
Amoxicillin/clavulanate	500/ 875 mg/ 8 h	No need for dose adjustment	500/ 875 mg/ 12- 24 h
Penicillin G	0'3- 1'2 million IU/ 6-12 h	50- 100% of the dose every 8- 12 h	25- 50% of the dose every 12 h
Clindamycin	300 mg/ 8 h	No need for dose adjustment	No need for dose adjustment
Doxiciclin	100 mg/ 24 h	No need for dose adjustment	No need for dose adjustment
Erythromycin	250- 500 mg/ 6 h	No need for dose adjustment	No need for dose adjustment
Metronidazole	250- 500 mg/ 6 h	Every 8-12 h	Every 12- 14 h
Azithromycin	500 mg/ 24 h, 3 days	No need for dose adjustment	No need for dose adjustment
ANTIFUNGALS			
Anfotericin	0'3- 1 mg/kg/ 24 h	No need for dose adjustment	0'3- 1 mg/ kg/ 24- 48 h
Fluconazol	100- 200 mg/ 24 h	50- 200 every 24 h	50- 100 every 24 h
ANALGESICS			
Paracetamol	500- 1000 mg/ 4- 6 h	No need for dose adjustment	No need for dose adjustment
Aspirin	Contraindicated (produces water retention, deterioration of renal function and risk of gastric hemorrhage)		
Ibuprofen	200- 600 mg/ 4- 6 h	No need for dose adjustment	No need for dose adjustment
Dihidrocodeine	10- 30 mg/ 4- 6 h	Decrease dose 25%	Decrease dose 25%

CC: Creatinin clearance.

Table 1. Dose adjustment according to creatinin clearance of the drugs more frequently prescribed in dentistry (6, 18).

natives to Cs, such as tacrolimus (14). Adverse effects of tacrolimus are similar to those of Cs but milder, and furthermore it does not produce gingival overgrowth (16). After performing a this change in the immunosuppressive therapy, Parraga- Linares et al (16) observed a fast resolution of the GO; however, other authors have reported a persistence of the GO after the change of Cs for tacrolimus (14).

a) *Patient with renal disease in conservative medical treatment.* For the dental treatment of these patients,

good communication with their nephrologist is highly recommended, in order to be aware of the stage of the pathology suffered and the treatment prescribed. Before any invasive dental procedure, possible hematologic problem in the patient should be studied. It is essential to remove any infective foci as soon as possible. Due to the frequent hypertension, blood pressure should be monitored during the procedures. When prescribing drugs, those that are nephrotoxic must be avoided (tetracyclines, aminoglycosides), some of them

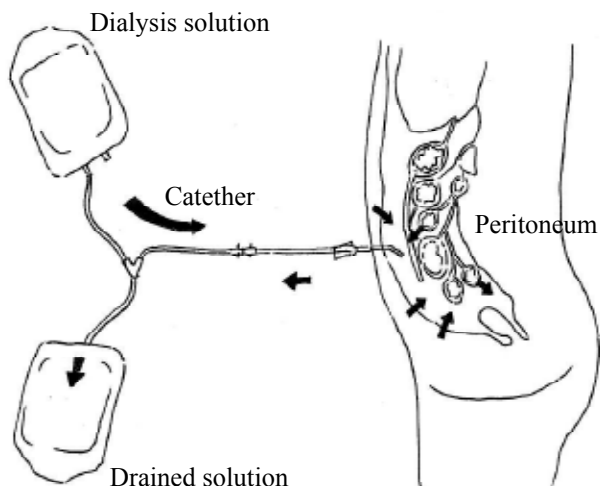


Fig. 1. Peritoneal dialysis process diagram.

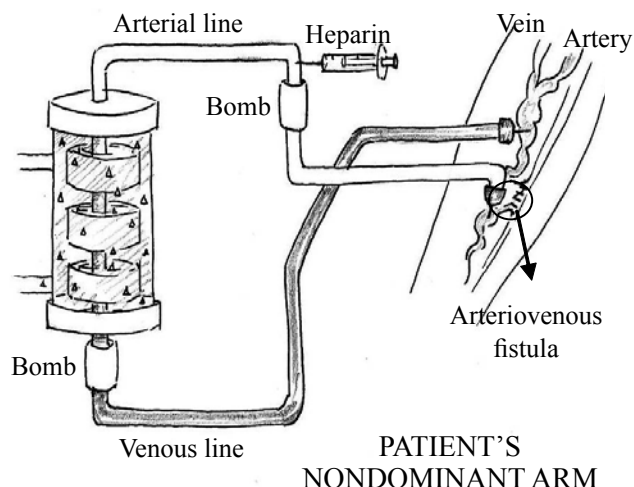


Fig. 2. Hemodialysis process diagram.

need a dose adjustment (as previously detailed). Apart from these considerations, no more exceptional measures must be performed.

b) Patient with renal disease in peritoneal dialysis. Dental management. In cases of peritoneal dialysis, a catheter placed in the abdominal wall and inserted in the peritoneum achieves access to the body, in order to remove nitrogen and other metabolic toxic products; through this, a hypertonic glucosated solution is introduced. Peritoneal membrane of the patient filters blood waste products by means of an osmotic mechanism, so

they would be transferred to the electrolytic solution and then evacuated to the exterior (1) (Fig. 1). This form of dialysis can be performed at home, but must be done every day (21).

These patients do not require special measures with regard to dental treatment, apart from the considerations already mentioned (2).

c) Patient with renal disease in hemodialysis. Dental management. In hemodialysis, the filtering process is carried out by a machine (dialyzer), outside the patient's body. Most of these patients receive this treatment 3 ti-

DENTAL MANAGEMENT OF THE PATIENT RECEIVING HEMODIALYSIS	
SITUATION	ATTITUDE
Patient with medical problems treated by other professionals	- Consultation with the nephrologist - Accurate medical history (medication prescribed)
High prevalence of arterial hypertension	Monitorization of blood pressure pre and postoperatively
Platelet dysfunction and anemia (bleeding tendency)	- Request hemostatic study before planning the surgery (time of bleeding, platelet recount, hematocrite, hemoglobin) - Local hemostatic measures
Heparin anticoagulation	Perform dental treatment the day not receiving dialysis, to be sure that there is no heparin in the blood (mean life of 4 hours)
Vascular access for hemodialysis	Avoid compression on the arm with the vascular access and never use it to measure blood pressure nor administering drugs intravenously
Disturbances in the metabolism and removal of drugs	Some drugs must not be prescribed and some need dose adjustment. Request the CC to estimate the GFR (see Table 1)
Renal osteodystrophy due to secondary hyperparathyroidism (late sign of chronic renal insufficiency)	- Bone more susceptible to fractures - Careful dental extraction technique to avoid fractures

CC: Creatinin clearance.

GFR: Glomerular filtrarion rate.

Table 2. Dental management of the patient receiving hemodialysis (19).

mes a week (21). In order to take the blood out of the body and to return it, it is necessary to have a vascular access. Permanent access is obtained by surgically connecting an artery to a vein, using a blood vessel (arteriovenous fistula) or a synthetic bridge (arteriovenous graft) (21). A special solution (dialysate) corrects the chemical disturbances and impurities of the blood, which is then introduced into the body (Fig. 2). During the process of hemodialysis, the patient's blood is anticoagulated with heparin to facilitate blood transit. For this reason, dental treatments with a risk of bleeding must not be performed the day of hemodialysis. If an emergency dental treatment must be performed, protamine sulphate (heparin antagonist) can be administered to block the anticoagulant effect (21). However, bleeding tendency would be still present due to platelet dysfunction and anemia, so usual hemostatic measures must be carried out (21). There is a risk of infection because of the vascular access, and of transmission of HBV, HCV and HIV, so this must be confirmed in patients receiving hemodialysis (6). Dental considerations for the patients in hemodialysis are synthesized in Table 2 (21).

d) Renal transplant patient. Dental management. These patients are immunosuppressed by medication. Maintenance of a proper oral health is especially important as

oral infections in transplant patients can contribute to its morbidity or even rejection (3). They are usually receiving a treatment of corticosteroids, calcineurin inhibitors (Cs, tacrolimus) and inhibitors of lymphocyte proliferation (azathioprine, mycophenolate mophetil) (3, 5). Long- standing treatment with high doses of corticosteroids produces an adrenal function suppression, which predisposes the patient to suffer an acute complication, adrenal crisis, when exposed to stressful situations (disease, infection, surgery). Furthermore, this chronic excess of corticosteroids can cause Cushing's syndrome (22). To minimize the risk of suffering an adrenal crisis in patients taking high doses of corticosteroids who are undergoing a surgical procedure, they should take a double dose of corticosteroids the day of the surgery. This supplement will not be necessary if the patient is being treated with low doses (less than 7.5 mg of prednisolone) or if the patient is undergoing a conservative treatment (22). However, the risk of developing an adrenal crisis after oral surgery procedures under local anesthesia is very low and the majority of dental treatments can be carried out without prescribing a supplement of corticosteroids (22). Considerations that must be taken into account in renal transplant individuals are described in Table 3.

DENTAL MANAGEMENT OF THE RENAL TRANSPLANT PATIENT	
SITUATION	ATTITUDE
Patient with medical problems treated by other professionals	- Consultation with the nephrologist - Accurate medical history (medication prescribed)
High prevalence of arterial hypertension	Monitorization of blood pressure pre and postoperatively
Platelet dysfunction and anemia (bleeding tendency)	- Request hemostatic study before planning the surgery (time of bleeding, platelet recount, hematocrite, hemoglobin) - Local hemostatic measures
Corticosteroid therapy	Risk of adrenal crisis if they are in a long- standing corticosteroid therapy: morning appointments and consider the need of supplemental corticosteroids
Immunossuppression	Prescribe antibiotic prophylaxis, if recommended by the nephrologist, prior to certain treatments: tooth extractions, periodontal treatments, subgingival placement of fibers or strips with antibiotic, placement of orthodontic bands and intraligamentous injections of local anesthetic
Disturbances in the metabolism and removal of drugs	Some drugs must not be prescribed and some need dose adjustment. Request the CC to estimate the GFR (see Table 1)
Gingival overgrowth (cyclosporin, nifedipin)	Perform exhaustive examinations of the gums and promote good oral hygiene. Consider surgical treatment

CC: Creatinine clearance.

GFR: Glomerular filtration rate.

Table 3. Dental management of renal transplant patient (3, 12, 19, 20).

Conclusions

The most important renal pathology in dentistry is CRD. Up to 90% of patients with CRD show oral signs and symptoms, such as bleeding tendency, greater susceptibility to infections and gingival overgrowth produced by cyclosporine.

As for dental considerations and management strategies for these patients, we should take into account that the drug dose adjustment must be done using creatinine clearance; before invasive dental procedures, a blood test must be requested (including hemostasia and blood recount). In transplant patients, the need of supplemental corticosteroid has to be considered. Hemodialysis and peritoneal dialysis do not indicate the need for an antibiotic prophylaxis. In hemodialyzed patients, dental treatment has to be performed the day they are not receiving hemodialysis.

References

- De Rossi SS, Glick M. Dental considerations for the patient with renal disease receiving hemodialysis. *J Am Dent Assoc.* 1996;127:211-9.
- Jover Cerveró A, Bagán JV, Jiménez Soriano Y, Poveda Roda R. Dental management in renal failure: patients on dialysis. *Med Oral Patol Oral Cir Bucal.* 2008;13:419-26.
- Proctor R, Kumar N, Stein A, Moles D, Porter S. Oral and dental aspects of chronic renal failure. *J Dent Res.* 2005;84:199-208.
- Garcez J, Limeres Posse J, Carmona IT, Feijoo JF, Diz Dios P. Oral health status of patients with a mild decrease in glomerular filtration rate. *Oral Surg Oral Med Oral Pathol Oral Radiol Endod.* 2009;107:224-8.
- Davidovich E, Davidovits M, Eidelman E, Schwarz Z, Bimstein E. Pathophysiology, therapy, and oral implications of renal failure in children and adolescents: an update. *Pediatr Dent.* 2005;27:98-106.
- Kerr AR. Update on renal disease for the dental practitioner. *Oral Surg Oral Med Oral Pathol Oral Radiol Endod.* 2001;92:9-16.
- de Francisco AL, Otero A. Occult chronic renal failure: EPIRCE study. *Nefrología.* 2005;25:66-71.
- de la Rosa García E, Mondragón Padilla A, Aranda Romo S, Bustamante Ramírez MA. Oral mucosa symptoms, signs and lesions, in end stage renal disease and non-end stage renal disease diabetic patients. *Med Oral Patol Oral Cir Bucal.* 2006;11:467-73.
- Leão JC, Gueiros LA, Segundo AV, Carvalho AA, Barrett W, Porter SR. Uremic stomatitis in chronic renal failure. *Clinics (Sao Paulo).* 2005;60:259-62.
- Antoniades DZ, Markopoulos AK, Andreadis D, Balaskas I, Patrikalou E, Grekas D. Ulcerative uremic stomatitis associated with untreated chronic renal failure: report of a case and review of the literature. *Oral Surg Oral Med Oral Pathol Oral Radiol Endod.* 2006;101:608-13.
- Sobrado Marinho JS, Tomás Carmona I, Loureiro A, Limeres Posse J, García Caballero L, Diz Dios P. Oral health status in patients with moderate-severe and terminal renal failure. *Med Oral Patol Oral Cir Bucal.* 2007;12:305-10.
- Seymour RA, Thomason JM, Nolan A. Oral lesions in organ transplant patients. *J Oral Pathol Med.* 1997;26:297-304.
- Hernández G, Arriba L, Frías MC, de la Macorra JC, de Vicente JC, Jiménez C, et al. Conversion from cyclosporin A to tacrolimus as a non-surgical alternative to reduce gingival enlargement: a preliminary case series. *J Periodontol.* 2003;74:1816-23.
- Lima RB, Benini V, Sens YA. Gingival overgrowth in renal transplant recipients: a study concerning prevalence, severity, periodontal, and predisposing factors. *Transplant Proc.* 2008;40:1425-8.
- Marshall RI, Bartold PM. Medication induced gingival overgrowth. *Oral Dis.* 1998;4:130-51.
- Párraga-Linares L, Almendros-Marqués N, Berini-Aytés L, Gay-Escoda C. Effectiveness of substituting cyclosporin A with tacrolimus in reducing gingival overgrowth in renal transplant patients. *Med Oral Patol Oral Cir Bucal.* 2009;14:429-33.
- Ciavarella D, Guiglia R, Campisi G, Di Cosola M, Di Liberto C, Sabatucci A, et al. Update on gingival overgrowth by cyclosporine A in renal transplants. *Med Oral Patol Oral Cir Bucal.* 2007;12:19-25.
- Lockhart PB, Loven B, Brennan MT, Fox PC. The evidence base for the efficacy of antibiotic prophylaxis in dental practice. *J Am Dent Assoc.* 2007;138:458-74.
- Gutiérrez JL, Bagán JV, Bascones A, Llamas R, Llena J, Morales A, et al. Consensus document on the use of antibiotic prophylaxis in dental surgery and procedures. *Med Oral Patol Oral Cir Bucal.* 2006;11:188-205.
- Poveda Roda R, Bagan JV, Sanchis Bielsa JM, Carbonell Pastor E. Antibiotic use in dental practice. A review. *Med Oral Patol Oral Cir Bucal.* 2007;12:186-92.
- Sharma DC, Pradeep AR. End stage renal disease and its dental management. *N Y State Dent J.* 2007;73:43-7.
- Miller CS, Little JW, Falace DA. Supplemental corticosteroids for dental patients with adrenal insufficiency: reconsideration of the problem. *J Am Dent Assoc.* 2001;132:1570-9.