

## Oral manifestations of celiac disease. A case report and review of the literature

Paulo Cesar da Silva <sup>1</sup>, Patrícia Del Vigna de Almeida <sup>2</sup>, Maria Ângela Naval Machado <sup>3</sup>, Antônio Adilson Soares de Lima <sup>3</sup>, Ana Maria Trindade Grégio <sup>4</sup>, Paula Cristina Trevilatto <sup>5</sup>, Luciana Reis Azevedo-Alanis <sup>5</sup>

- (1) Graduation Student
- (2) Post-Graduation Student, Department of Stomatology
- (3) Associate Professor and Chairman, Department of Oral Pathology
- (4) Associate Professor and Chairman, Department of Pharmacology
- (5) Associate Professor, Department of Stomatology. School of Dentistry, Pontificia Universidade Católica do Paraná

### Correspondence:

Dr. Luciana Reis Azevedo-Alanis  
Rua Imaculada Conceição 1155,  
Prado Velho 80215-901  
Curitiba – Paraná – Brazil  
E-mail: l.azevedo@pucpr.br

Received: 07/11/2007  
Accepted: 13/02/2008

da Silva PC, de Almeida PV, Machado MÂN, de Lima AAS, Grégio AMT, Trevilatto PC, Azevedo-Alanis LR. Oral manifestations of celiac disease. A case report and review of the literature. Med Oral Patol Oral Cir Bucal. 2008 Sep1;13(9):E559-62.

© Medicina Oral S. L. C.I.F. B 96689336 - ISSN 1698-6946  
<http://www.medicinaoral.com/medoralfree01/v13i9/medoralv13i9p559.pdf>

### Indexed in:

-Index Medicus / MEDLINE / PubMed  
-EMBASE, Excerpta Medica  
-SCOPUS  
-Índice Médico Español  
-IBECs

### Abstract

Celiac disease is a chronic intestinal disease caused by intolerance to gluten associated with poor digestion and absorption of the majority of nutrients and vitamins, which may affect both developing dentition and oral mucosa. The aim of this study is to make a brief review of the literature about celiac disease and to report on a clinical case, showing the impact it may have on the general and oral health. A 39-year-old woman reported the presence of diarrhea, nausea, flatulence, colic, difficulty with falling asleep, lack of appetite and loose of 18 Kg in the last two years. She also noted the appearance of symptomatic lesions in the mouth. These lesions had a mean duration of a month and occurred in any region of the oral mucosa, particularly on the tongue. Multiples ulcerations were found in the sublingual caruncula region, at the vestibular fornix and at the lingual apex. Topical treatment was instituted for the oral lesions with immediately relief of the symptoms. The diagnosis of celiac disease was established by means of medical clinical exam, biopsy of the small intestine, and by the presence of specific antibodies in the blood. The patient has been instructed to follow a gluten-free diet. Multiprofessional action with the involvement of a gastroenterologist and other health professionals, such as dentists, is important for diagnosing the disease and guiding the patient with celiac disease to achieve a good quality of life.

**Key words:** Celiac disease, gluten, oral manifestations, oral health, treatment.

## Introduction

Celiac disease (CD) or gluten-sensitive enteropathy is a permanent intolerance, mediated by T lymphocytes, to the polypeptide fragments of gluten, a protein contained in some cereals, such as wheat, rye, barley and oats. This disease is characterized by total or sub-total atrophy of the proximal small intestine villusities, resulting in poor absorption of the majority of nutrients and vitamins. It generally manifests itself from the sixth month of life, coinciding with the introduction of cereals into the diet (1).

Its prevalence is very variable from country to country and predominantly affects white individuals. However, in countries with a high degree of racial miscegenation, it has been described in mulattos (2).

Classical CD is the most frequent pattern. It manifests itself in the first years of life with chronic diarrhea, vomiting, irritability, anorexia, weight loss, growth deficit, abdominal pain and distension, variable degrees of compromised nutritional status, iron-deficiency anemia pallor, and gluteal muscle atrophy (2).

The neo-classical or atypical pattern presents later and the digestive manifestations are absent or, when present, are hardly relevant. The lesions in the oral mucosa or the defects in dental enamel may be the only signs present in atypical cases (3).

The diagnosis of CD should be based on three main pillars: clinical exam, histopathologic exam of the small intestine and investigation for seric markers (1). Oral signs and symptoms (tooth enamel hypoplasia, oral mucosa ulcers, pain or burning of the tongue) in celiac patients are of fundamental importance as diagnostic aids for this disease (2). The main serologic markers described are anti-gliadin (AGA), antireticulin (ARA) and antiendomysium (EmA) antibodies. EmA antibodies have shown a high degree of specificity and sensitivity at various stages of the disease, and are at present considered the best tracer test (4). Histologic evaluation shows abnormal proximal small intestine mucosa with atrophied or absent villusities, increased crypt lengths and number of intraepithelial lymphocytes (5).

The treatment of CD is basically dietary, based on excluding gluten from the diet throughout life, both in symptomatic and asymptomatic individuals, and nutritional requirements must be met in accordance with the patient's age. In addition to diet, the celiac patient must pay attention to the composition of medications prescribed for him/her, since there may be gluten present as excipient in capsules, pills or oral suspensions (6). When the disease is not treated, there is the possibility of complications, such as: sterility, osteoporosis, endocrinopathies, neurological and psychiatric disturbances, hepatic and conjunctive system diseases and association with auto-immune diseases (herpetiform dermatitis, diabetes mellitus, selective IgA deficiency and thyroid diseases). Moreover, celiac patients

have a greater risk for developing enteropathy-associated non-Hodgkin's T cell lymphoma, carcinoma of the pharynx and esophagus and adenocarcinoma of the small intestine compared to non-celiac patients (2).

## Case Report

A feoderma woman (dark skinned), 39-years-old, was referred to the Stomatology clinic at the Dental Clinic of PUCPR with the main complaint of "presence of aphtas in the mouth, with a frequency that I hardly ever had before".

During anamnesis the patient reported being an ex-smoker and gastrointestinal disease carrier. As from the age of 37 years she frequently began to present diarrhea, nausea, cramps, flatulence, abdominal distension, colic, difficulty with falling asleep, lack of appetite and since then lost 18 Kg of weight. The patient noted the appearance of lesions in the mouth approximately a year ago. The lesions had a mean duration of a month and occurred in any region of the oral mucosa, particularly on the tongue. They were large or small symptomatic ulcerations and sometimes occurred in an isolated pattern.

In the physical intraoral exam, the presence of lesions in three regions of the oral mucosa was found: 1) symptomatic well-defined ulceration covered by fibrin, with an erythematous halo, located in the anterior portion of the floor of the mouth and affecting the sublingual caruncula and the lingual frenulum (Fig 1); 2) extensive symptomatic ulceration, covered by fibrinous tissue, with an erythematous halo, in the posterior region at the vestibular fornix on the right side, extending to the buccal mucosa (Fig 2) and 3) an extensive erythematous area presenting several small symptomatic ulcerations at the lingual apex (Fig 3).

Topical treatment was instituted for the oral lesions with dexametasone (Decadron Elixir®) – daily mouthwash of 5 mL (1 teaspoon) every 6 hours – for fifteen days, as the lesions caused discomfort and made it difficult for the patient to eat. The symptoms were relieved immediately and the ulcerations disappeared 4 to 5 days after treatment began.

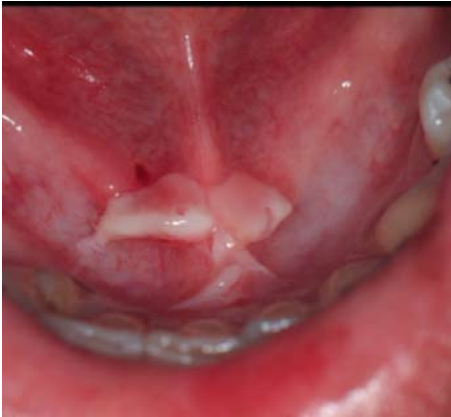The diagnosis of celiac disease was established by means of medical clinical exam, biopsy of the small intestine and by the presence of anti-gliadin and antiendomysium antibodies in the blood. Since then, the patient has been instructed to follow a gluten-free diet.

During the initial appointment, the patient also reported a sensation of dry mouth. To investigate the presence of hyposalivation, the total stimulated salivary flow was determined (0.8315mL/min).

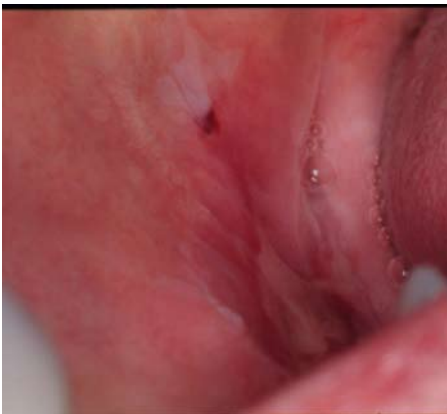## Discussion

CD may affect both developing dentition and oral mucosa (7).

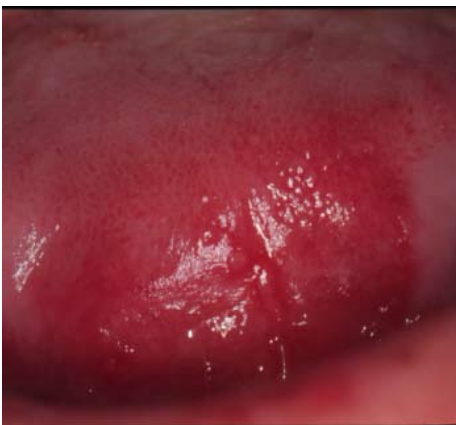
Enamel hypoplasia is a frequent sign of CD, possibly being the only manifestation in untreated celiac children



**Fig 1.** Ulceration on the sublingual caruncula region.



**Fig 2.** Ulceration in the posterior region at the fornix of the vestibule on the right side.



**Fig 3.** Erythematous lesion on the apex of the tongue.

and adolescents (2). Incisors and permanent first molars are the most affected teeth, perhaps because the odontogenesis phase coincides with the active phase of the disease (8). Enamel hypoplasia is caused by hypocalcemia during enamel formation. In addition to hypocalcemia, other systemic factors are associated with enamel hypoplasia, such as malnutrition and vitamin D and A deficiency (9). Gluten intake and its consequences may be responsible for the enamel defects in celiac patients. An immunologic process induced by gluten may occur between the ages of six and seven years of age, which affects the organ producing enamel, resulting in defects in the formation of this tissue (10).

The main oral signs associated with CD are angular cheilitis, glossitis and depapillated tongue (1). The redness and pain in the tongue with papillar atrophy are related to the vitamin B12, folic acid and iron deficiencies, whose absorptions in the small intestine may be affected by CD. The ulcerations described in the clinical case corroborate the reports of Lahteenoja et al.(3), who found burning or pain in the tongue, erythema or ulcerations located on the lips, palate, mucosa or tone of celiac patients. Ulcers were the most common type of lesion in the mouth, presenting in a papular or erosive form, generally with an erythematous margin.

It is still not clear whether the oral lesions represent a direct manifestation of CD or whether they occur as a result of the indirect effects of poor absorption on the cells of the basal layer of the mucosa, which is in the process of division and already predisposed to irritation by a pre-existent disease (11).

Some authors found that individuals with CD have a high predominance of recurrent aphthous stomatitis and suggest that these may be an early indicator or a sign of CD (3). Others researchers emphasize that a significant number of patients with recurrent aphthous stomatitis may present a mild form of gluten-sensitive enteropathy (12,13). According to Sedghizadeh et al.(14), recurrent aphthous ulcerations are an indicator of risk and not a risk factor for CD.

The differential diagnosis of oral lesions present in CD includes recurrent aphthous stomatitis and traumatic injuries. Regarding recurrent aphthous stomatitis, the differential diagnosis is made principally from the history, clinical presentation and development (13). The histologic condition is not specific and the lesions cure themselves spontaneously in time (14,15).

In some cases, CD may contribute to the development of protein-calorie malnutrition and depending on the age at which this is established, it contributes to the appearance of oral alterations, such as delayed tooth eruption, diminished size of the teeth, problems in enamel formation and salivary gland dysfunction (10).

Regarding salivary gland dysfunctions, the alterations caused by gluten do not affect the total stimulated sali-

vary flow, but the composition of saliva may be affected, causing alterations in the total protein, albumin, IGA, IGM, amylase and myeloperoxidase concentrations (7). Meanwhile, Lähteenoja et al.(3) observed that celiac patients frequently complained of dry mouth symptoms. This corroborates the theory that the subjective sensation of dry mouth may occur even in the presence of normal salivary flow (16,17).

In the clinical case described, the patient presented low salivary flow (0.8315mL/min), in addition to reporting the dry mouth sensation. In this case, it is suggested that the xerostomia could have been the consequence of the diminished salivary flow (16). However, factors such as the type of saliva (rest or stimulated), procedures and time of collection, composition and source (larger or smaller salivary glands), in addition to individual variations and physiological predispositions, can contribute to the patient's report of dry mouth and its relationship with hyposalivation (17).

Multiprofessional action with the involvement of a gastroenterologist and other health professionals, such as dentists, is important for diagnosing the disease and guiding the patient with CD to achieve a good quality of life.

## References

1. Catassi C, Rättsch IM, Fabiani E, Rossini M, Bordicchia F, Candela F, et al. Coeliac disease in the year 2000: exploring the iceberg. *Lancet*. 1994 Jan 22;343(8891):200-3.
2. Rauen MS, Back JCV, Moreira EAM. Doença celiaca: sua relação com a saúde bucal. *Rev Nutr*. 2005 Apr;18(2):271-6.
3. Lähteenoja H, Toivanen A, Viander M, Mäki M, Irjala K, Riihää I, et al. Oral mucosal changes in coeliac patients on a gluten-free diet. *Eur J Oral Sci*. 1998 Oct;106(5):899-906.
4. Hill ID. What are the sensitivity and specificity of serologic tests for celiac disease? Do sensitivity and specificity vary in different populations. *Gastroenterology*. 2005 Apr;128(4 Suppl 1):S25-32.
5. Guevara GP. Enfermedad celíaca. *Rev Chil Pediatr*. 2002;73(4):394-7.
6. Olson GB, Gallo GR. Gluten in pharmaceutical and nutritional products. *Am J Hosp Pharm*. 1983 Jan;40(1):121-2.
7. Lenander-Lumikari M, Ihalin R, Lähteenoja H. Changes in whole saliva in patients with coeliac disease. *Arch Oral Biol*. 2000 May;45(5):347-54.
8. Aguirre JM, Rodríguez R, Oribe D, Vitoria JC. Dental enamel defects in celiac patients. *Oral Surg Oral Med Oral Pathol Oral Radiol Endod*. 1997 Dec;84(6):646-50.
9. Seow WK. Enamel hypoplasia in the primary dentition: a review. *ASDC J Dent Child*. 1991 Nov-Dec;58(6):441-52.
10. Mäki M, Aine L, Lipsanen V, Koskimies S. Dental enamel defects in first-degree relatives of coeliac disease patients. *Lancet*. 1991 Mar 30;337(8744):763-4.
11. Abenavoli L, Proietti I, Leggio L, Ferrulli A, Vonghia L, Capizzi R, et al. Cutaneous manifestations in celiac disease. *World J Gastroenterol*. 2006 Feb 14;12(6):843-52.
12. Veloso FT, Saleiro JV. Small-bowel changes in recurrent ulceration of the mouth. *Hepatogastroenterology*. 1987 Feb;34(1):36-7.
13. Jimenez Y, Bagan JV, Milian M. Minor recurrent aphthous stomatitis: Clinic characteristics hematologic deficiencies in 60 patients. *Med Oral*. 1996 Sep;1(1):11-14.
14. Sedghizadeh PP, Shuler CF, Allen CM, Beck FM, Kalmar JR. Celiac disease and recurrent aphthous stomatitis: a report and review of the literature. *Oral Surg Oral Med Oral Pathol Oral Radiol Endod*. 2002 Oct;94(4):474-8.
15. Esparza Gómez G. Management of aphtous stomatitis. *Med Oral*. 2003 Nov-Dec;8(5):383.
16. Närhi TO. Prevalence of subjective feelings of dry mouth in the elderly. *J Dent Res*. 1994 Jan;73(1):20-5.
17. Moore PA, Guggenheimer J, Etzel KR, Weyant RJ, Orchard T. Type 1 diabetes mellitus, xerostomia, and salivary flow rates. *Oral Surg Oral Med Oral Pathol Oral Radiol Endod*. 2001 Sep;92(3):281-91.